

## Case Report

### Pleural tuberculosis masquerading as metastatic malignancy

Mohamed Mirghani Osman, F.R.C.P\*, Abdullahi Mahgoub Zaki, MD, FCCP\*\*

Department of Medicine, University of Khartoum, Sudan\*

Department of community medicine, Omdurman Islamic University, Sudan\*\*

#### Abstract

Tuberculosis involvement of the pleura usually presents as pleural effusion, empyema or pleural thickening. In this communication we report a case of unilateral pleural tuberculosis presenting as multiple nodular masses without effusion, which raised the possibility of metastatic malignancy. Histopathology of the nodules confirmed the diagnosis of tuberculosis; and with standard antituberculosis therapy they disappeared and the patient's symptoms improved.

**Keywords:** tuberculosis, pleural masses, metastases.

#### Introduction:

Pulmonary tuberculosis is a common worldwide infection. The radiological features show considerable variation; but in most cases they are characteristic enough to suggest a diagnosis<sup>(1)</sup>. Pleural involvement which is a form of extrapulmonary tuberculosis, most commonly presents as pleural effusion.

Abnormal radiological presentation of pleural tuberculosis has been previously reported<sup>(2)</sup>.

#### Case Report

A 22-year-old previously well, non smoking male presented with a four months history of weight loss, right-sided pleuritic chest pain and dyspnoea on exertion. He had no cough or haemoptysis. There was no past history of chest disease or contact with tuberculosis patient. Examination showed that he was ill and febrile but normotensive. Chest examination revealed a dull percussion note and diminution of breath sounds on the right side of the chest. A few non-tender soft tissue swellings (each measuring 4-5 cm in diameter) were noted over his back and the right lateral aspect of the chest. No abnormality was detected in the other systems.

Biochemical profile was normal. Hemoglobin was 12.2 gm/dl, WBC: 5.8 x 10<sup>9</sup>/L, Mantoux test 15mm with 1 TU, ESR 48mm 1st hr, HIV serology negative. X ray of the chest (Fig. 1) showed multiple nodular discrete and confluent pleural masses of different sizes without calcification involving the right hemithorax. CT scan (Fig. 2) confirmed that the masses were pleural based. Lung fields were clear and there was no pleural effusion. Sputum smears and cultures were negative for acid-fast bacilli. Fine needle biopsy of the soft tissue masses over the back revealed caseation with positive stain for acid-fast bacilli.

---

#### Correspondent author:

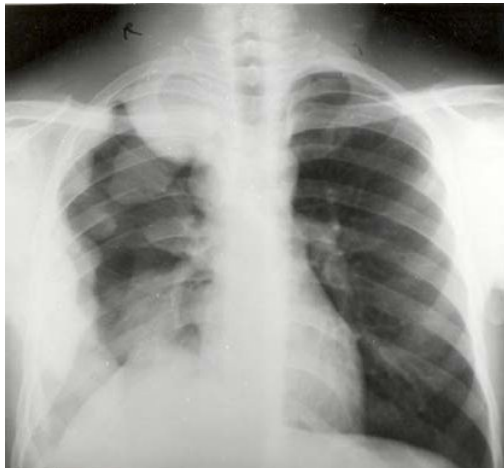
Mohamed Mirghani Osman

**Email:** momiosman54@yahoo.com

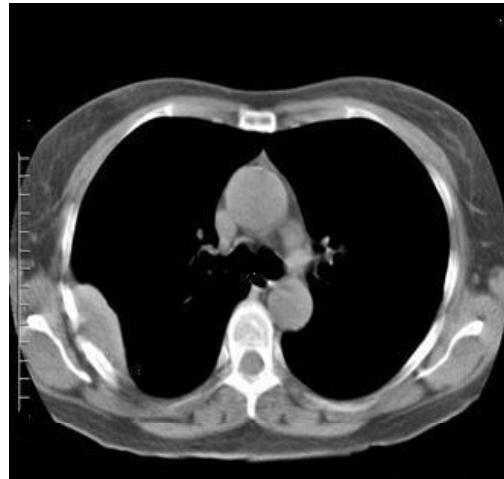Case Report  
Pleural tuberculosis masquerading as metastatic malignancy

A diagnosis of pleural tuberculosis was made and the patient was started on anti-tuberculosis treatment using the standard short-course regimen (isoniazid- rifampicin - pyrazinamide - ethambutol) for 6 months. He gained weight and became asymptomatic. The ESR came down to 20mm 1st hour. This was accompanied by

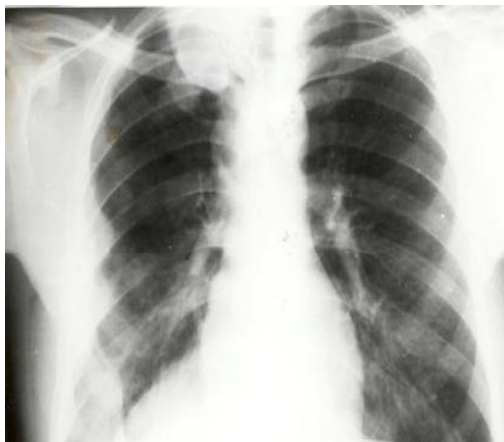significant reduction in size of the soft tissue swellings. Follow up chest X-rays showed reduction in the size of the pleural masses at the fourth month (Fig. 3), then almost complete disappearance (Fig. 4) by the end of chemotherapy. Regular follow up visits there after showed no sign of recurrence of these nodules.



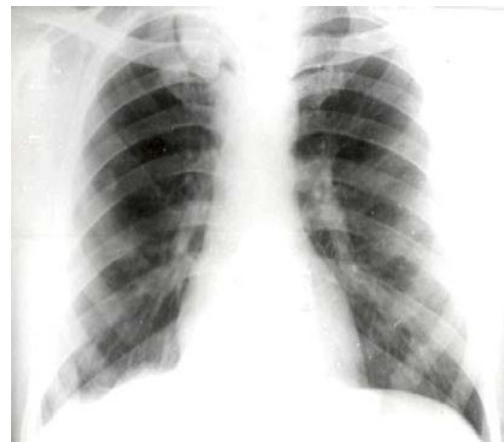
**Fig. 1:** X-ray showing multiple nodular discrete and confluent pleural masses of different sizes without calcification involving the right hemithorax.



**Fig. 2:** CT scan of the chest demonstrating a pleural mass.



**Fig. 3** X-ray chest showing reduction in size of the pleural masses.



**Fig. 4:** X-ray showing almost complete disappearance of the pleural masses.

Case Report

Pleural tuberculosis masquerading as metastatic malignancy

## Discussion

In this case the initial impression was a form of pleural neoplasm (primary or secondary) based on the clinical and radiological findings. There was, however, neither a history of exposure to asbestos nor an obvious clinical source for a primary neoplasm. However, the positive fine needle aspiration result of the soft tissue masses made ultrasound guided needle biopsy of the pleural masses unnecessary. The latter is a valuable method for diagnosing pathology of the pleural masses<sup>(3)</sup>.

Pleural thickening has been reported with tuberculous effusion, haemothorax, empyema, recurrent pneumothorax, rheumatoid arthritis, pneumoconiosis (asbestos, silica<sup>(4)</sup>, kaolin<sup>(5)</sup>) and rarely with thymoma<sup>(6)</sup>. Nodular pleural masses may occur with metastases, mesothelioma<sup>(7)</sup>, myeloma<sup>(8)</sup>, after talc pleurodesis<sup>(9)</sup> and rarely with sarcoidosis<sup>(10)</sup>.

## References

1. Andreu J, Caceres J, Pallisa E. Radiologic manifestations of pulmonary tuberculosis. *European J Radiology* 2004;51:139-149.
2. Blunt SB, Harries MG. Discrete pleural masses without effusion in a young man: an unusual presentation of tuberculosis. *Thorax* 1989;44:436-437.
3. Hsu WH, Chiang CD, Hsu JY. Value of ultrasonically guided needle biopsy of pleural masses: an underutilized technique. *J Clin Ultrasound* 1997; 25:119-125.
4. Zaren EH, Colby TV, Roggli V. Silica induced pleural disease: an unusual case mimicking malignant mesothelioma. *Chest* 1997; 112:1436-1438.

Thoracic tuberculosis presenting solely as multiple pleural masses without pleural effusion is extremely rare. The first case was described in 1989 in a 29-year-old young male patient<sup>(2)</sup>.

In 2002, Atasoy et al described a patient with thoracic tuberculosis presenting as discrete pleural nodules associated with a parasternal mass without any parenchymal changes or mediastinal lymphadenopathy on computed tomography<sup>(11)</sup>.

To the best of our knowledge, the present case is the third in literature where thoracic tuberculosis has presented as multiple pleural masses.

In conclusion tuberculosis is a very common problem in developing countries and can mimic several chest problems including malignancy. Confirmation of the diagnosis with sputum smears, culture, or histology is mandatory since treatment is gratifying.

5. Chaudhary BA, Kaner GJ, Pool WH. Pleural thickening in mild kaolinosis. *South Med J* 1997; 90: 1106-1109.
6. Shih DF, Wang JS, Tseng HH. Primary pleural thymoma. *Arch Pathol Lab Med* 1997;121:79-82.
7. Miller BH, Rosado-de-Christenson ML, Mason AC. Malignant pleural mesothelioma. *Radiographics* 1996; 16:613-644.
8. Cabrera A, Klein JS. Bilateral pleural masses and shortness of breath associated with multiple myeloma. *Chest* 1997;111:1750-1753.
9. Murray JG, Patz EF, Erasmus JJ. CT appearance of the pleural space after talc pleurodesis. *Am J Roentgenol* 1997; 169:89-91.

10. Loughney E, Higgins BG. Pleural sarcoidosis: a rare presentation. *Thorax* 1997;55:200-201.
11. Atasoy C, Kaya A, Fitoz S, Yildrem Z. Discrete pleural nodules associated with a parasternal mass: an unusual manifestation of tuberculosis. *J Thoracic Imaging* 2002;17:74-77.